

# Is There a Role for Laser in DME?

OCT mapping can help to answer this question.

CHARLES MAYRON, MD, FACS

Increasingly, the published clinical evidence points to the superiority of anti-VEGF injections over laser treatment for center involving diabetic macular edema (CI-DME).<sup>1-3</sup> As good as anti-VEGF is, there are still a number of patients that need supplemental therapy.

In the DRCR.net Protocol T, approximately 50% of patients needed therapy in addition to regular injections.<sup>4</sup> They were given supplemental laser photocoagulation. We also know that in real life situations, there is underutilization of anti-VEGF across all macular diseases.

Patients get tired of doctor appointments and start to miss them. Physicians are pressured by cost containment measures and sympathetic to patient fatigue, and the frequency of injections is diluted. The result is a situation that is a far cry from the precision of clinical trials; one that requires an alternative treatment.

## IF NOT INJECTIONS, WHAT?

Laser photocoagulation applied in DME has changed significantly since the first ETDRS studies. In the original focal/grid laser applications ocular chromophores absorb laser energy, converting it to heat until the temperature is high enough to damage the natural transparency of the retina, giving the typical white appearance.<sup>5,6</sup>

Unique to MicroPulse for grid laser is the ability to apply subthreshold energy at a photostimulative level in a low intensity/high density confluent pattern that essentially chops the laser beam into a series of very short pulses, with pauses in between each pulse that allow the tissue to cool.

The Tx-Cell Scanning Laser Delivery System (Iridex) allows a confluence of spots that cannot be done manually. A duty cycle of 5% with appropriate energy insures a safer application that allows dissipation of heat, eliminating

collateral damage and confining the laser treatment to the retinal pigment epithelium.<sup>7</sup>

Research has shown that MicroPulse laser (MPL) delivery, rather than damaging the cells, has a photostimulatory effect. MPL therapy initiates a transcriptional activation of cytokine expression, which releases growth factors and upregulates matrix metalloproteinases.<sup>8</sup>

The farther away you  
are from the central  
subfield, the more  
liberty you have with  
delay of the resolution  
of the edema.

The MPL does not create any immediate or long-term damage to the tissue that can be detected by clinical examination, intravenous fluorescein angiography (IVFA), or fundus autofluorescence (FAF).<sup>9</sup>

## CREATING A PROTOCOL

If we rake through the existing case reports, small clinical trials and substantial data on MPL, we see that it works best in individuals with good glycemic control, and on patients with central retinal thickness (CRT) less than 400  $\mu\text{m}$ .<sup>10</sup>

Charles Mayron, MD, FACS, is the founder of Capital Retina Associates in Latham, NY. He has no financial interest in any of the products or devices mentioned. Dr. Mayron may be reached via e-mail at [cmayron@aol.com](mailto:cmayron@aol.com).

Thus, I start by investigating my patients' history to see what level of hemoglobin A1C control they have. What is their level now? How long has it been at that level? Have they recently developed DME or is this a known chronic problem?

If a patient has good A1C control maintained over some time, I suspect their diabetic retinopathy is stable and MPL maybe an option. If the patient demonstrates severe non-proliferative or worse retinopathy, my concern is to reduce the diabetic severity score in an attempt to reverse progression of the disease. I will not compromise the retina, so I turn to anti-VEGF when edema is present in those situations.

If the A1C is too high or only recently in control, I prefer injections. If a patient has mild CI-DME that is "asymptomatic," and their A1C levels have been well controlled for some time, and they have CRT less than 350  $\mu\text{m}$ , I will offer photostimulative MPL as an option for the diffuse edema.

It is also important to evaluate the location of the DME. The farther away you are from the central subfield (ETDRS overlay as a guide), the more liberty you have with delay of the resolution of the edema. Laser works slowly with durability, steroids work faster than laser, but anti-VEGF therapy works best for DME; it's a question of what therapy is practical for which type of patient. Focal laser photocoagulation is best for circinate edema originating in a subadjacent subfield which is typically a "one and done" approach.

## USING COLORS RATHER THAN NUMBERS

Most physicians use spectral domain optical coherence tomography (SD-OCT) to assess macular edema and get a single number for thickness of a particular subfield.

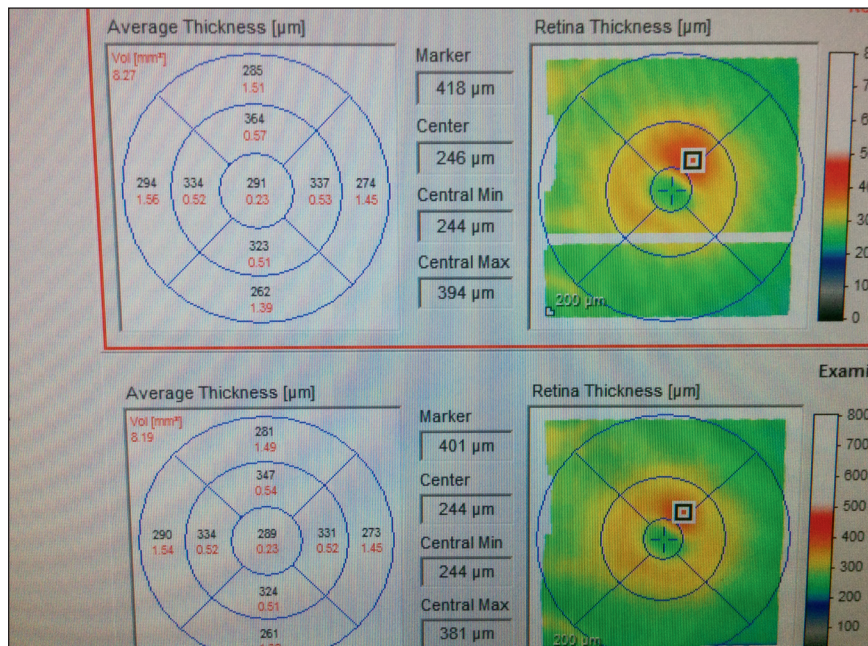
In CI-DME, the central subfield must be yellow or better, and the patient must have good glycemic control for me to perform MPL.

However, I find it much more useful to use the color OCT thickness map available with the Heidelberg Spectralis SD-OCT because it is representative of the actual thickness rather than an average value (Figure 1).


White represents a thickness of 500-800  $\mu\text{m}$ , red is 400-500  $\mu\text{m}$ , orange is 350-375  $\mu\text{m}$ , yellow is 300-350  $\mu\text{m}$ , and all areas less than 300  $\mu\text{m}$  are green. Once clinically significant DME (CSME) has been diagnosed, I treat according to these thickness maps.

In non-CI-DME that is clinically significant, if the subfields adjacent to the center are pink or better, I will use MPL as the primary treatment. If the subfields are red or worse, I start treatment with anti-VEGF therapy and once the thickness map shows pink or better, I will switch to MPL.

In CI-DME, the central subfield must be yellow or better and the patient must have good glycemic control for me to perform MPL. If the central subfield is orange or worse, I inject anti-VEGF medication until the subfield is yellow or better (Figure 2). Then I perform photostimulative MPL, follow the



**Figure 1. nCI-DME superior Spectralis SD-OCT thickness map subadjacent subfield average value vs the marker value demonstrates why color is a more accurate measure of the actual thickness than the subfield value. This is why "treating by the colors" is helpful for successful photostimulative MPL because this therapy is thickness dependent.**



**Figure 2. Top image: CI-DME Spectralis SD-OCT thickness map before the use of anti-VEGF; the central subfield is red, and the subadjacent subfields are white. Middle image: After three monthly anti-VEGF injections the above SD-OCT thickness map is less edematous. The central subfield is yellow, and the subadjacent subfields are pink or better. This represents a favorable map for photostimulative MPL. Bottom image: After four MPL treatments applied in three- to four-month intervals to the macular edema in the middle panel, the SD-OCT thickness map demonstrates total resolution of the macular edema (after two years of follow up, the patient's VA is 20/20).**

patient monthly and repeat MPL every 3 to 4 months as long as the treatment map, vision, and patient are responding (**Figure 2**).

I evaluate the OCT thickness map both prior to anti-VEGF injections and after, and treat all areas that had edema, even if it has now subsided, with MPL. I perform a thorough, confluent treatment as this has been found to have an advantage over standard grid laser.<sup>11</sup>

### MY PATIENT EXPERIENCE

The theory is that MPL reduces the need for anti-VEGF injections in appropriately selected patients. I began using the Iridiex IQ 577 laser in January 2014, and have evaluated a subset of my patients over 24 months. I looked at 58 eyes of 40 patients. Forty-five eyes had CI-DME, and 13 eyes had non CI-DME. Of the 45 eyes with CI-DME, 15 responded well and did not need anti-VEGF injections following laser therapy. Seven of these 15 had anti-VEGF prior to beginning laser treatment, but not once laser treatment began. The average baseline CMT was 380  $\mu\text{m}$ , which

reduced to an average of 276  $\mu\text{m}$  following treatment.

There were also 8 eyes with non CI-DME that responded well to MPL and did not need subsequent anti-VEGF injections. This results in a total of 23 eyes that were able to avoid continued injections of pharmacotherapy due to MPL. From the total of 58 eyes, 35 eyes were not able to sustain sufficient improvement with at least two laser treatments, and had to return to retinopharmacotherapy.

### IN THE INTEREST OF THE PATIENT

Our number one goal is always to rid the macula of edema without sacrificing the best possible visual acuity and not adversely affect outcome. For those patients with symptomatic or moderate CI-DME, that means always using anti-VEGF pharmacotherapy first without delay.

However, for the right patient, we can do them a great service by offering photostimulative MPL therapy alone; as well as in select cases subsequent to anti-VEGF injections when the thickness map is optimized to potentially reduce the need for future retinopharmacotherapy. **RP**

### REFERENCES

1. Mitchell P, Bandello F, Schmidt-Erfurth U, et al; RESTORE study group. The RESTORE study: ranibizumab monotherapy or combined with laser versus laser monotherapy for diabetic macular edema. *Ophthalmology*. 2011;118:615-625.
2. Berger A, Sheidow T, Cruess AF, et al. Efficacy/safety of ranibizumab monotherapy or with laser versus laser monotherapy in DME. *Can J Ophthalmol*. 2015;50:209-216.
3. Regnier S, Malcolm W, Allen F, Wright J, Bezyak V. Efficacy of anti-VEGF and laser photocoagulation in the treatment of visual impairment due to diabetic macular edema: a systemic review and network meta-analysis. *PLoS One*. 2014;16:9:e102309.
4. Wells JA, Glassman AR, Ayala AR, et al; Diabetic Retinopathy Clinical Research Network. Aflibercept, bevacizumab, or ranibizumab for diabetic macular edema: Two-year results from a comparative effectiveness randomized clinical trial. *Ophthalmology*. 2016;123:1351-1359.
5. Kulkarni GR. Laser-tissue interaction studies for medicine. *Bull Mat Sci*. 1988;11:239-244.
6. Sivaprasad S, Elagouz M, McHugh D, et al. Micropulsed diode laser therapy: evolution and clinical application. *Surv Ophthalmol*. 2010;55:516-530.
7. Dorin G. The treatment of diabetic retinopathy (DR): Laser surgery or laser therapy? *Retina Today*. Available at: [www.retinatoday.org/rt/rt.nsf/url?OpenForm&id=65](http://www.retinatoday.org/rt/rt.nsf/url?OpenForm&id=65).
8. Flaxel C, Bradle J, Acott T, Samples JR. Retinal pigment epithelium produces matrix metalloproteinases after laser treatment. *Retina*. 2007;27:629-634.
9. Vujosevic S, Bottega E, Casciano M, et al. Micropertometry and fundus autofluorescence in diabetic macular edema: subthreshold micropulse diode laser versus modified early treatment diabetic retinopathy study laser photocoagulation. *Retina*. 2010;30:908-916.
10. Vujosevic S, Ferdinando M, Lonhgin E, et al. Subthreshold micropulse yellow laser versus subthreshold micropulse infrared laser in center-involving DME: Morphologic and functional safety. *Retina*. 2015;35:1594-1603.
11. Lavinsky D, Cardillo JA, Melo LA Jr, et al. Randomized clinical trial evaluating mEDTRS versus normal or high-density micropulse photocoagulation for diabetic macular edema. *Invest Ophthalmol Vis Sci*. 2011;52:4314-4323.